

Gender: F Age: 52
Social Security Number: XXX-XX-6678
Patient ID/Case Number:

Proficiency Test Client Account
ProficiencyTest, Physician MD
1234 Proficiency Test St.
Nowhere, NY 10543
(555) 555-5555



Date of Procedure: 10/22/2018
Date Received: 10/22/2018

Clinical Information: 1-FNA, Thyroid, left upper (2.6 cm, complex with solid component)
2-FNA, Thyroid, left lower (1.0 cm, complex with cystic component)
3-FNA, Thyroid, right mid (1.8 cm, complex with cystic component)

Thyroid Cytology Report

RESULTS

1: Diagnosis

*Left Upper Thyroid: **Atypia of Undetermined Significance, Not Otherwise Specified (Bethesda 2017 Category III). Thyroid mutation panel is pending.***

Microscopic Description: The Papanicolaou stained ThinPrep and the histopathologic sections of the aspirated material (cell block) show small follicular cells with uniform nuclei admixed with clusters of atypical follicular cells with enlarged nuclei with prominent nucleoli and anisonucleosis in a background of thin colloid.

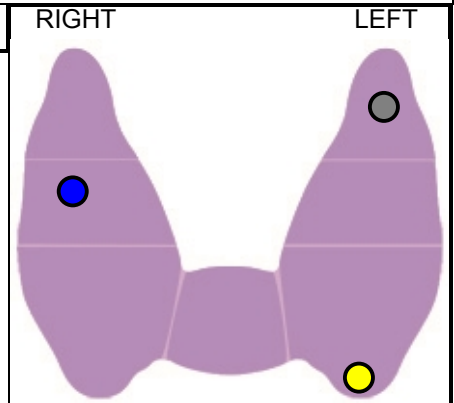
Gross Description: Received in a cytolyt tube labeled with the patient name and "Site 1" as "Left Upper Thyroid" are 30 ml of light turbid fluid for cellular enhancement and cell block preparation, designated 1A. Received is a 1.5 ml molecular ThyroSeq tube. jp

2: Diagnosis

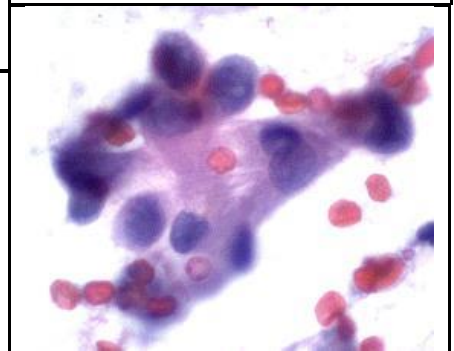
*Left Lower Pole: **Benign follicular nodule, consistent with nodular goiter and post-hemorrhagic cystic change (Bethesda 2017 Category II). (ICD: E04.9)***

Microscopic Description: The Papanicolaou-stained ThinPrep and the histopathologic sections of the aspirated material (cell block) show small follicular cells with uniform nuclei, thin colloid, cyst-lining cells and hemosiderin-laden macrophages.

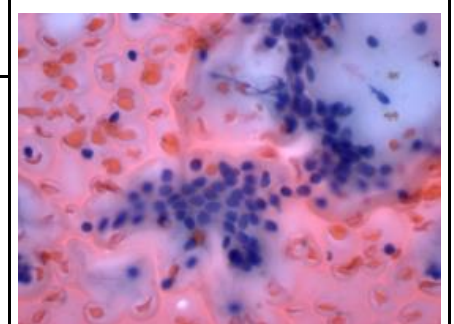
Gross Description: Received in a cytolyt tube labeled with the patient name and "Site 2" as "Left Lower Pole" are 20 ml of turbid fluid for cellular enhancement and cell block preparation, designated 2A. Received is a 1.5 ml molecular ThyroSeq tube. jp



PHOTOMICROGRAPH



Specimen 1: *Left Upper Thyroid*
Atypical follicular cells



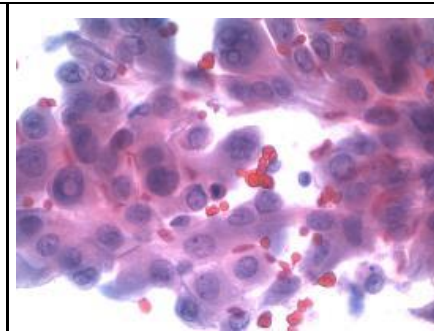
Specimen 2: *Left Lower Pole*
Follicular cells

3: Diagnosis

*Right Mid Thyroid: **Malignant; Papillary Thyroid Carcinoma with Cystic Features (Bethesda 2017 Category VI). Please see comment.***

Microscopic Description: The Papanicolaou stained ThinPrep and the histopathologic sections of the aspirated material (cell block) show neoplastic follicular cells arranged in small groups with irregular borders, sheets, papillae or microfollicles. Tumor cells have "histiocytoid" morphology with abundant, granular or vacuolated cytoplasm. The nuclei are enlarged, oval, irregular, crowded with nucleoli, grooves and intranuclear pseudoinclusions (INPIs). Background shows macrophages, some with hemosiderin and colloid.

Gross Description: Received in a cytolyt tube labeled with the patient name and "Site 3" as "Right Mid Thyroid" are 25 ml of clear fluid for cellular enhancement and cell block preparation, designated 3A. Received is a 1.5 ml molecular ThyroSeq tube. jp



Specimen 3: Right Mid Thyroid
Atypical follicular cells with nuclear grooves and pseudoinclusions

Comments

Specimen #1 Left Upper: Thyroid mutation panel is pending and will be reported separately.
Case reviewed at the Daily Consensus Conference and the group concurs with the diagnosis. Reported to Dr. Smith and report faxed on 10/22/18.

Electronically signed out by:

Dr. Rana Hoda

(877) 258-9310

Report Date:
10/22/2018

2nd ed., TBSRTC 2017: Implied Risk of Malignancy & Recommended Clinical Management

Diagnostic Category	Risk of Malignancy if NIFTP ≠ CA (%)	Risk of Malignancy if NIFTP = CA (%)	Usual Management*
Nondiagnostic or Unsatisfactory	5-10	5-10	Repeat FNA with ultrasound guidance
Benign	0-3	0-3	Clinical and sonographic follow-up
Atypia of Undetermined Significance or Follicular Lesion of Undetermined	6-18	~10-30	Repeat FNA, molecular testing, or lobectomy
Follicular Neoplasm or Suspicious for a Follicular Neoplasm	10-40	25-40	Molecular testing, lobectomy
Suspicious for Malignancy	45-60	50-75	Near-total thyroidectomy or lobectomy
Malignant	94-96	97-99	Near-total thyroidectomy or lobectomy

Please see the details of clinical management in the references below.

References for the table

1. The Bethesda System for Reporting Thyroid Cytopathology: Definitions, Criteria, and Explanatory Notes, Edition 2. By Syed Z. Ali and Edmund Cibas. Springer International Publishing, Switzerland, 2017.
2. Haugen BR et al. 2015 ATA Management Guidelines for Adult Patients with Thyroid Nodules and Differentiated Thyroid Cancer: The ATA Guidelines Task Force on Thyroid Nodules and Differentiated Thyroid Cancer. Thyroid. 2016 Jan;26(1):1-133.

Images included in this report are for information only and are not intended for diagnosis.

Some tests performed at CBLPath Inc have not been cleared or approved for specific uses by the U.S. Food and Drug Administration (FDA). The FDA has determined that such clearance or approval is not necessary. In accordance to CLIA '88 requirements, this laboratory has verified the validity and accuracy of these tests for clinical purposes. CBLPath is regulated under the Clinical Improvement Amendments Acts of 1988 (CLIA) as qualified to perform high complexity testing.

End of Report